

Ultrasound-guided injection of platelet-rich plasma in a patient with an ischeotibial muscle injury

Inyección guiada por ultrasonido de plasma rico en plaquetas en un paciente con lesión en el origen de la musculatura isquiotibial

*Lina Andrea Gomez, **Javier Fernando Bonilla Briceño, ***Angélica Patricia Martínez Vasquez, ****Ana Luisa Muñoz

*Universidad de la Sabana (Colombia), **Universidad Nacional de Colombia (Colombia), ***Caja de Compensación Familiar (Colombia), ****Universidad Antonio Nariño (Colombia)

Abstract. Platelet-rich plasma (PRP) is a platelet concentrate that is obtained after centrifugation and may influence tissues healing by growth factors released after platelet degranulation. This treatment has been used for the management of muscles, ligaments, and tendinopathy injuries with promising results, there is still limited clinical evidence for its use. In this study we present the report of a case of a 50-year-old soccer player who presented an injury at the origin of the ischeotibial muscles of the right thigh. On day 13, after the injury, autologous Platelet Rich Plasma (APRP) was applied under ultrasound (US) guidance. The control by US and Nuclear *Magnetic Resonance* (NMR) was performed two weeks after the PPR application, which show resolution of the hematoma, and tissue regeneration. The patient returned to his sports activity at week 12 after the PRP treatment, without pain and with improvement in muscular strength. The PRP treatment could be an option to avoid surgical procedures in athletes because it could improve muscular strength and healing, added it is easy to obtain and apply. Further studies are necessary to reach a consensus regarding clinical indications, processing and PRP application techniques that rebound in alternatives to improve the quality of life of patients in a cost-effective way, as well as shortening the recovery time of athletes.

Keywords: ischeotibial muscle injury, athletic injuries, grow factors.

Resumen. El plasma rico en plaquetas (PRP) es un concentrado de plaquetas que se obtiene después de centrifugación y puede influir en la curación de los tejidos por los factores de crecimiento liberados después de la desgranulación de las plaquetas. La terapia con PRP ha sido utilizada para el manejo de lesiones de tejidos blandos, como músculos, ligamentos y tendones con resultados prometedores. aunque la evidencia clínica actual para su uso es limitada. En este estudio presentamos el reporte del caso de un jugador de fútbol de 50 años que presentó lesión en el origen de la musculatura isquiotibial del muslo derecho. El día 13, después de la lesión, se le aplicó Plasma Rico en Plaquetas Autólogo (PRPA) guiado por ultrasonido (US). El control por US y resonancia magnética nuclear (RMN) se realizó dos semanas después de la aplicación del PRP, mostrando recuperación de la lesión y resolución del hematoma. El paciente volvió a realizar actividades deportivas en la semana 12 después del tratamiento, sin dolor y con mejoría de la fuerza muscular. El tratamiento con PRP podría ser una opción para evitar procedimientos quirúrgicos mejorando la fuerza muscular y la curación de la musculatura isquiotibial, adicionalmente el PRP es fácil de obtener y aplicar. De igual manera se necesitan más estudios para llegar a un consenso sobre las indicaciones clínicas, el procesamiento y las técnicas de aplicación de PRP que redunden en alternativas para mejorar la calidad de vida de los pacientes de una manera costo-efectiva, así como acortar el tiempo de recuperación de los atletas.

Palabras clave: lesión del músculo isquiotibial, alteraciones en atletas, factores de crecimiento.

Introduction

Ischeotibial injuries are a common type of injury with a prevalence of 12-37% in the sports field, characterized by debility and difficulty in running (Ashley N. Startzman, DO; Oliver Fowler, BS; Dominic Carreira, 2017), having as a consequence an average of 8 to 24 days lost from competition or sportive activity,

and moreover a high re-injury rate, up to 34%, as this is more severe for both symptoms and recovery time that the first trauma (Di Trani Lobacz, Glutting, & Kaminski, 2016)

The diagnosis and follow up of ischeotibial muscle injury are usually made by nuclear magnetic resonance (NMR) and ultrasonography (US). The treatment protocol for muscle injuries is generally aimed at reducing inflammation and pain in the acute phase. Later, treatment focuses on strengthening and improving the range of motion of the injured muscle (Ali K, 2012).

Hamstring injuries can be separated based on

proximal, muscle belly, and distal injuries, more commonly the proximal and distal injuries require surgery. Nonsurgical treatments focus on eccentric strengthening. High grade complete tears are better managed surgically, with reattachment to the injured tendon or ischial tuberosity (Arner, McClincy, & Bradley, 2019).

PRP has been postulated as a treatment that can help in the healing of different tissue disorders. Autologous platelet-rich plasma is a platelet concentrate that contains a number of platelets above the baseline value (150,000 to 350,000/ μ L), and an increased concentration of the growth factors of its alpha granules; (TGF- α 1, PDGF, bFGF, VEGF, EGF, IGF-1), which are concentrated through the centrifugation process to release supraphysiologic amounts of these growth factors and cytokines to an injury site and augment the natural healing process (Le, Enweze, DeBaun, & Dragoo, 2018).

Currently, there is no consensus about management strategies to this type of injury, in general the classical management aims to reduce inflammation by means of anti-inflammatory therapy, immobilization, rest, compression, and corticosteroids, which have demonstrated slow results and also a high possibility of relapses (DiTrani Lobacz et al., 2016). Additionally, some of these injuries should be treated by means of surgery, which presents a high associated morbidity. Nevertheless, in any case, rehabilitation is imperative, however there is a marked variability in the composition and timing of rehabilitation protocols (Raya-González, Gómez Piqueras, & Sánchez-Sánchez, 2018).

Consequently, is necessary to implement and standardize other less invasive treatment alternatives that allow shortening the time to complete fitness and to return to physical activity, as well as re-injury reduction, improving the patient quality of life (Setayesh, Villarreal, Gottschalk, Tokish, & Choate, 2018). A promising treatment option is the use of bioactive substances such as platelet-rich plasma (PRP), a product that has been used for the management of muscle, ligament, and tendinopathy injuries with promising results, but currently there is limited clinical evidence. (Andia, Martin, & Maffulli, 2018).

The aim of this report was to demonstrate clinical improvement in a patient with ischeotibial muscle injury following treatment with platelet-rich plasma (PRP).

Case Presentation

This research was approved by the Institutional Ethics

Committee of the Antonio Nariño University from Colombia, and the patient enrolled, responded voluntarily to an informed consent formulary at the beginning of the study.

The patient include in this study was a 50-year-old man, with dominant right member, who has practiced different sports since adolescence, and suffered an injury during a soccer match. During the fifth minute of the game and after he started to a race for the ball, he felt a snap at the base of the right buttock associated with an intense pain that made him unable to walk. Ice was placed on the location of the injury, and an oral analgesic and intramuscular anti-inflammatory was administered. Twenty-four hours later, the orthopedist found edema without ecchymosis, limitation of knee flexion. The same day, a pelvic radiograph was taken which reported the absence of recent fracture (data not shown). The NMR and the US, report a proximal hamstring injury classified as Munich 4, showed edema and fluid around the lesion and tear of the superior calf, with involvement of the sciatic nerve (Mueller-Wohlfahrt et al., 2013). Photo 1, panels A and B).

The patient was immobilized with a thigh brace, and the management consisted of raised leg, ice for 72 hours, and non-steroidal anti-inflammatory drugs orally if needed. Physiotherapy was started the day after the injury, according to the patient's evolution and condition (Table 1). The patient continued the weight-bearing and walking protocol.

Due to the lack of consensus in treatment of ischeotibial muscle injury, and considering the high morbidity rates of surgical treatment (Hölmich, 2015).

Table 1.
Physiotherapeutic protocol followed (Jayaseelan, Moats, & Ricardo, 2014; Prentice, 2001)

| Time of evolution (weeks) | Treatment |
|---------------------------|---|
| 1st | Cryotherapy (local application with package and cry thigh massage). Isometric exercises with slow and controlled contractions Contrast of heat and cold, electro stimulation with TENS (Transcutaneous electrical nerve stimulation) and application of therapeutic ultrasound (favor healing process and reduce inflammation). |
| 2nd and 3rd | Exercises in closed kinetic chains in supine and bipedal, exercises of active-assisted ischeotibial muscle contraction in prone, and isotonic without load. Strengthening of quadriceps, gastrocnemius with elastic bands. Stabilization exercises, pelvic floor strengthening, and abdominals. CORE. Concentrated ischeotibial muscle exercises with elastic bands, in sub-maximum ranges and with slow contractions. |
| 4th, 5th, 6th | Exercises with fit ball in supine, bipedal, in open, and closed kinetic chains. Uni and bipodal proprioceptive work on unstable surfaces. The gluteal, quadriceps, gastrocnemius, pelvic floor, and abdominal muscles are continued. Exercises of displacements and changes of speed, with wide, anterior, and lateral stride. |
| 7th-8th | Jogging Isotonic exercises with resistance and long lever arms. Proprioceptive work on unstable surfaces and exercises in open and closed kinetic chains. Starts strengthening by bicycle. |
| 9th-10th | Eccentric ischeotibial muscle, exercises with elastic bands and fit ball. Initiates phymetric exercises, anteriorly, and laterally. |
| 11th-12th | Ride a bicycle. Return to sports activity. |

Looking at the advances made in the management of various musculoskeletal injuries with the use of regenerative medicine therapies, particularly with the use of PRP, we wanted to know what would be the effect on this patient (Guillodo, 2015)

We use a manual obtaining and processing technique standardized by our research group. Platelet rich plasma was obtained from the same patient, from 50 mL of peripheral blood, were centrifuged at 1500 rpm for 10 minutes, then, in a biological safety cabinet the platelet-poor plasma was separated and 8 mL of platelet-rich plasma was obtained. The patient had a baseline platelet count of 223,000/ul and after using our protocol for obtaining PRP, he had 825,000/ul, an amount that was applied in a single dose, at the site of injury (Gómez, Escobar, & Peñuela, 2015). A single dose of autologous PRP was injected by ultrasound guidance on day 13 after the injury occurred (Photo 1, panel C).

Two weeks after the Platelet Rich Plasma treatment, an imaging control was performed with US and NMR, where resolution of the hematoma and progression towards scar changes and tissue regeneration were evidenced. Photo 2, panels A and B).

After week twelve, the patient began to practice volleyball, noticing an improvement in muscle strength, without pain or limitation. (Physical therapy evaluation (Table 2).

Table 2.
Physical therapy evaluation

Initial evaluation:

- Posture: Lower limbs equal in height, retroverted pelvis, bilateral genuine, right knee in semi-flexion, preserved plantar arches. Pain: 3/10 according to the verbal analogue scale.
- Joint mobility: Patient completes range of motion of hip and knee passively. Active goniometry shows limitation of knee flexion of 125°. The extension of the knee with hip flexion at 90° does not present pain or limitation, however, with hip flexion above 90°.
- Pain and extension limitation (-10°) is present.
- Muscular strength: According to the Javier Daza muscle strength scale. Hip: Psoas 3 + / 5, gluteus maximus 3/5, gluteus medius 3 + / 5, adductors 3 + / 5, tensor fascia lata 3 + / 5, hip rotators 3 + / 5. Knee: Quadriceps 4/5, Hamstrings 2 + / 5. Standing neck: 3 + / 5 gastrocnemius, tibialis and fibulae.
- Flexibility: Moderate retractions of psoas, tensor fascia lata and iliotibial band, hip adductors. Quadriceps not assessable due to limitation of knee flexion, hamstrings not assessable due to current condition.
- Trophism: Presents alteration of thigh muscle trophism of comparatively 1 centimeter. It presents discontinuity of the muscular belly to the contraction.
- Gait: Decreased heel strike phase, poor weight-bearing in the lower right limb. Proprioception: Presents moderate deficit for the position of the toes, heels and unipodal.

Evaluation week 12:

- Pain: Deny. Joint mobility: Patient completes range of motion of hip and knee passively and actively.
- Muscle strength: Hip: Psoas 3 + / 5, gluteus maximus 3 + / 5, gluteus medius 4/5, adductors 3 + / 5, tensor fascia lata 4/5, hip rotators 3 + / 5. Knee: Quadriceps 4/5, Hamstrings 3 + / 5. Standing neck: 3 + / 5 gastrocnemius, tibialis and fibulae.
- Flexibility: Moderate retractions of the psoas, tensor fascia lata, iliotibial band, hamstrings and hip adductors. Minor quadriceps.
- Trophism: Presents alteration of thigh muscle trophism of comparatively 0.5 centimeter. March: Without alteration in its phases. Proprioception: Presents slight deficit for the position of the toes, heels and unipodal.

Finally, a radiological control was performed at week 16 after treatment with PRP, where a complete scarring process was evident with no sign of a residual hematoma (Photo 2, panels C and D). After 1 year of follow-up there was no relapse.

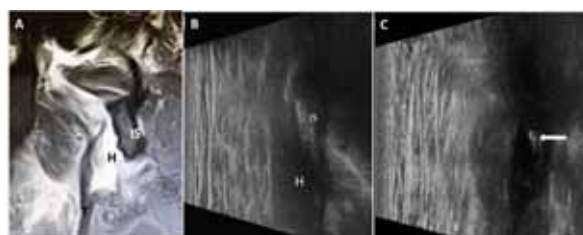


Photo No.1 Complex proximal rupture of the isquiotibial tendon. A. Coronal NMR T2. B and C. Ultrasound. In B hematoma location. In C needle placement of PRP. H (hematoma); IS (ischion); T (Tendon). Arrow: Needle.

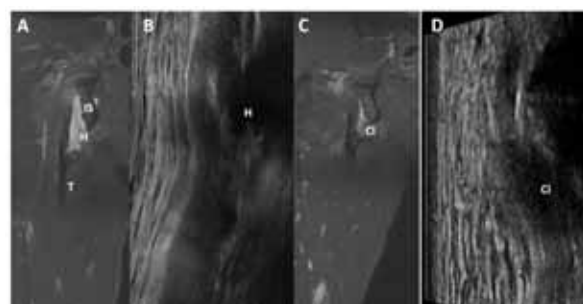


Photo No. 2. Control after PRP treatment. Panels A and B control two weeks post-PRP. A. Coronal proton density (PD) NMR, fat suppression. B: Ultrasound panoramic longitudinal view. Panels C and D control 16 weeks post-PRP. C. Coronal PD NMR, fat suppression. D. Longitudinal plane ultrasound. Ci (scar), H (hematoma), IS (ischion), T (tendon).

Discussion

Hamstrings injuries are one of the most frequent injuries on soft tissues for competitive and recreational athletes, keeping them away from the competition. The presented case involves a proximal hamstring injury observed mainly in athletes, where surgical treatment is usually suggested (Harris, Griesser, Best, & Ellis, 2011) an option with high morbidity. If a non-surgical management is performed it traditionally focuses on the use of nonsteroidal anti-inflammatory drugs. Other strategies, are also used, such as immobilization, compression, injections of corticosteroids, and physiotherapy which is focused on stretching and eccentric strengthening to facilitate the recovery of tendinopathies, however all of them have demonstrated slow results with reduced patient satisfaction percentage, because of the lower rates of return to pre-injury conditions, and also with the possibility of relapses (Harris et al., 2011).

Due to the high incidence of this type of lesion, the low percentage of success of the current treatment strategies, which is evidenced by the persistence of the symptoms and the high rates of recurrence (mainly in the first two weeks after returning to sports) Michael Common runners injuries evaluation and management it is necessary to implement and standardize other less invasive treatment alternatives that lead to improve the percentage of recovery and relapse rate reduction.

Recently, PRP is being used as a therapeutic strategy in bone and tendon regeneration, where specifically,

due to the regulation exerted by its growth factors, the formation of new tenocytes and support structure are favored naturally. In addition, the production of collagen also contributes to angiogenesis and tendon regeneration (Mautner & Kneer, 2014). One of the growth factors present in PRP is TGF- β , which is known to act in most stages of tendon recovery and has several effects such as regulation of proteinases, stimulation of cell migration, union of fibronectin, and stimulation of collagen production (Barile et al., 2016).

Some authors found no statistically significant differences between athletes suffering from acute injuries in the ischeotibial muscle when they were treated with a single injection of PRP or placebo. (Molloy, Wang, & Murrell, 2003).

Rossi LA et al, studied the time of return to sports activities in a group of 75 patients diagnosed with acute muscle injuries, compared autologous PRP therapy combined with a rehabilitation programme or a rehabilitation programme only. A single PRP injection combined with a rehabilitation programme reduced the time to return to sport compared to a rehabilitation programme only. (Kaux & Emonds-Alt, 2018)

Zanon y colaboradores, confirmed the safety of PRP in treating hamstring lesions in a large series of professional football players, showed a smaller scar and repair tissue (Zanon et al., 2016)

PRP has been used in different musculoskeletal disorders with contradictory results regarding its clinical efficacy, these results are mainly based on the lack of standardized protocols for obtaining and applying PRP, methodology used, and characteristics of the subjects studied. (Mariani & Pulsatelli, 2020)

The biological factors as well as the route of administration are determinants in the effectiveness of PRP treatment (Kon et al., 2020). Therefore, we proposed that protocols must be standardized, and a single injection can be administered directly at the injury localization by means of ultrasound guidance, a flexible, available and low cost tool.

The results of this research support the use of PRP as a therapy in the management of ischeotibial muscle injury, along with a physiotherapy program, will shorten the patient's recovery by reducing the tissue regeneration recovery time. In addition, the patient returned to sports activities 12 weeks later, without recidivism after 1 year of follow-up, due to the biological effects of growth factors and to the use of a standardized PRP extraction and processing method, as well as ultrasound guidance, a technique with low risk of

complications, and that improves the effectiveness of the PRP treatment, by facilitating access to injuries.

There are variations in the content of growth factors by age and sex, these differences could be correlated with biological variations and the results obtained in each patient. (Gómez et al., 2015)

Ultrasonography has proven to be a valuable tool to guide the placement of substances such as PRP, by providing the direct visualization of the needle in the area where the tear is located and allowing a follow-up of the lesion (Draghi, Robotti, Jacob, & Bianchi, 2010).

Conclusion

PRP could be considered for the ischeotibial muscle injury management protocol due to the patient's recovery time and minimal side effects. Additionally, ultrasonography has proven to be a valuable tool to guide the placement of substances such as PRP, by favoring the direct visualization of the needle in the area where the tear is located and allowing a follow-up of the lesion. The improvement of the patient was probably due to the treatment received with PRP and physical therapy. Further studies are necessary to reach a consensus

regarding clinical indications, processing, and PRP application technique that rebound in alternatives to improve the quality of life of patients in a cost-effective way, shortening the recovery time of athletes.

More quality clinical studies will be needed in the future to support the positive outlook regarding the use of PRP, to make definitive recommendations regarding its use as a treatment

Funding/Support

This study was supported by the authors

References

- Ali K, L. J. (2012). Hamstring strains and tears in the athlete. *Clin Sports Med.*, 31((2)), 263–272. <https://doi.org/10.1016/j.csm.2011.11.001>
- Andia, I., Martin, J. I., & Maffulli, N. (2018). Platelet-rich Plasma and Mesenchymal Stem Cells. *Sports Medicine and Arthroscopy Review*, 26(2), 59–63. <https://doi.org/10.1097/JSA.0000000000000191>
- Arner, J. W., McClincy, M. P., & Bradley, J. P. (2019). Hamstring Injuries in Athletes. *Journal of the American Academy of Orthopaedic Surgeons*, 27(23), 868–877. <https://doi.org/10.5435/JAAOS-D-18-00741>

- Ashley N. Startzman, DO; Oliver Fowler, BS; Dominic Carreira, M. (2017). Proximal Hamstring Tendinosis and Partial Ruptures. *Orthopedics*, 1(40), e574–e582. <https://doi.org/https://doi.org/10.3928/01477447-20170208-05>
- Barile, A., La Marra, A., Arrigoni, F., Mariani, S., Zugaro, L., Splendiani, A., ... Masciocchi, C. (2016). Anaesthetics, steroids and platelet-rich plasma (PRP) in ultrasound-guided musculoskeletal procedures. *The British Journal of Radiology*, 89(1065), 20150355. <https://doi.org/10.1259/bjr.20150355>
- Di Trani Lobacz, A., Glutting, J., & Kaminski, T. W. (2016). Clinical practice patterns and beliefs in the management of hamstrings strain injuries. *Journal of Athletic Training*, 51(2), 162–174. <https://doi.org/10.4085/1062-6050-51.3.08>
- Draghi, F., Robotti, G., Jacob, D., & Bianchi, S. (2010). Interventional musculoskeletal ultrasonography: Precautions and contraindications. *Journal of Ultrasound*, 13(3), 126–133. <https://doi.org/10.1016/j.jus.2010.09.004>
- Gómez, L. A., Escobar, M., & Peñuela, O. (2015). Standardization of a Protocol for Obtaining Platelet Rich Plasma from blood Donors; a Tool for Tissue Regeneration Procedures. *Clinical Laboratory*, 61(8), 973–980. Retrieved from <http://www.ncbi.nlm.nih.gov/pubmed/26427141>
- Guillodo, Y. (2015). Platelet-rich plasma (PRP) treatment of sports-related severe acute hamstring injuries. *Muscles Ligaments and Tendons Journal*. <https://doi.org/10.11138/mltj/2015.5.4.284>
- Harris, J. D., Griesser, M. J., Best, T. M., & Ellis, T. J. (2011). Treatment of Proximal Hamstring Ruptures – A Systematic Review. *International Journal of Sports Medicine*, 32(07), 490–495. <https://doi.org/10.1055/s-0031-1273753>
- Hölmich, P. (2015). Groin injuries in athletes—development of clinical entities, treatment, and prevention. *Danish Medical Journal*, 62(12), B5184. Retrieved from <http://www.ncbi.nlm.nih.gov/pubmed/26621401>
- Jayaseelan, D. J., Moats, N., & Ricardo, C. R. (2014). Rehabilitation of Proximal Hamstring Tendinopathy Utilizing Eccentric Training, Lumbopelvic Stabilization, and Trigger Point Dry Needling: 2 Case Reports. *Journal of Orthopaedic & Sports Physical Therapy*, 44(3), 198–205. <https://doi.org/10.2519/jospt.2014.4905>
- Kaux, J.-F., & Emonds-Alt, T. (2018). The use of platelet-rich plasma to treat chronic tendinopathies: A technical analysis. *Platelets*, 29(3), 213–227. <https://doi.org/10.1080/09537104.2017.1336211>
- Kon, E., Di Matteo, B., Delgado, D., Cole, B. J., Dorotei, A., Dragoo, J. L., ... Sánchez, M. (2020). Platelet-rich plasma for the treatment of knee osteoarthritis: an expert opinion and proposal for a novel classification and coding system. *Expert Opinion on Biological Therapy*, 1–14. <https://doi.org/10.1080/14712598.2020.1798925>
- Le, A. D. K., Enweze, L., DeBaun, M. R., & Dragoo, J. L. (2018). Current Clinical Recommendations for Use of Platelet-Rich Plasma. *Current Reviews in Musculoskeletal Medicine*, 11(4), 624–634. <https://doi.org/10.1007/s12178-018-9527-7>
- Mariani, E., & Pulsatelli, L. (2020). Platelet Concentrates in Musculoskeletal Medicine. *International Journal of Molecular Sciences*, 21(4), 1328. <https://doi.org/10.3390/ijms21041328>
- Mautner, K., & Kneer, L. (2014). Treatment of Tendinopathies with Platelet-rich Plasma. *Physical Medicine and Rehabilitation Clinics of North America*, 25(4), 865–880. <https://doi.org/10.1016/j.pmr.2014.06.008>
- Molloy, T., Wang, Y., & Murrell, G. A. C. (2003). The Roles of Growth Factors in Tendon and Ligament Healing. *Sports Medicine*, 33(5), 381–394. <https://doi.org/10.2165/00007256-200333050-00004>
- Mueller-Wohlfahrt, H. W., Haensel, L., Mithoefer, K., Ekstrand, J., English, B., McNally, S., ... Uebliacker, P. (2013). Terminology and classification of muscle injuries in sport: The Munich consensus statement. *British Journal of Sports Medicine*, 47(6), 342–350. <https://doi.org/10.1136/bjsports-2012-091448>
- Prentice, W. (2001). *Técnicas de rehabilitación en la medicina deportiva*. Paidotribo.
- Raya-González, J., Gómez Piqueras, P., & Sánchez-Sánchez, J. (2018). Effect of an eccentric load resistance training program on the rehabilitation of medial collateral ligament injuries. A case study. *Retos*, 2041(33), 157–161.
- Setayesh, K., Villarreal, A., Gottschalk, A., Tokish, J. M., & Choate, W. S. (2018). Treatment of Muscle Injuries with Platelet-Rich Plasma: a Review of the Literature. *Current Reviews in Musculoskeletal Medicine*, 11(4), 635–642. <https://doi.org/10.1007/s12178-018-9526-8>
- Zanon, G., Combi, F., Combi, A., Perticarini, L., Sammarchi, L., & Benazzo, F. (2016). Platelet-rich plasma in the treatment of acute hamstring injuries in professional football players. *Joints*, 04(01), 017–023. <https://doi.org/10.11138/jts/2016.4.1.017>